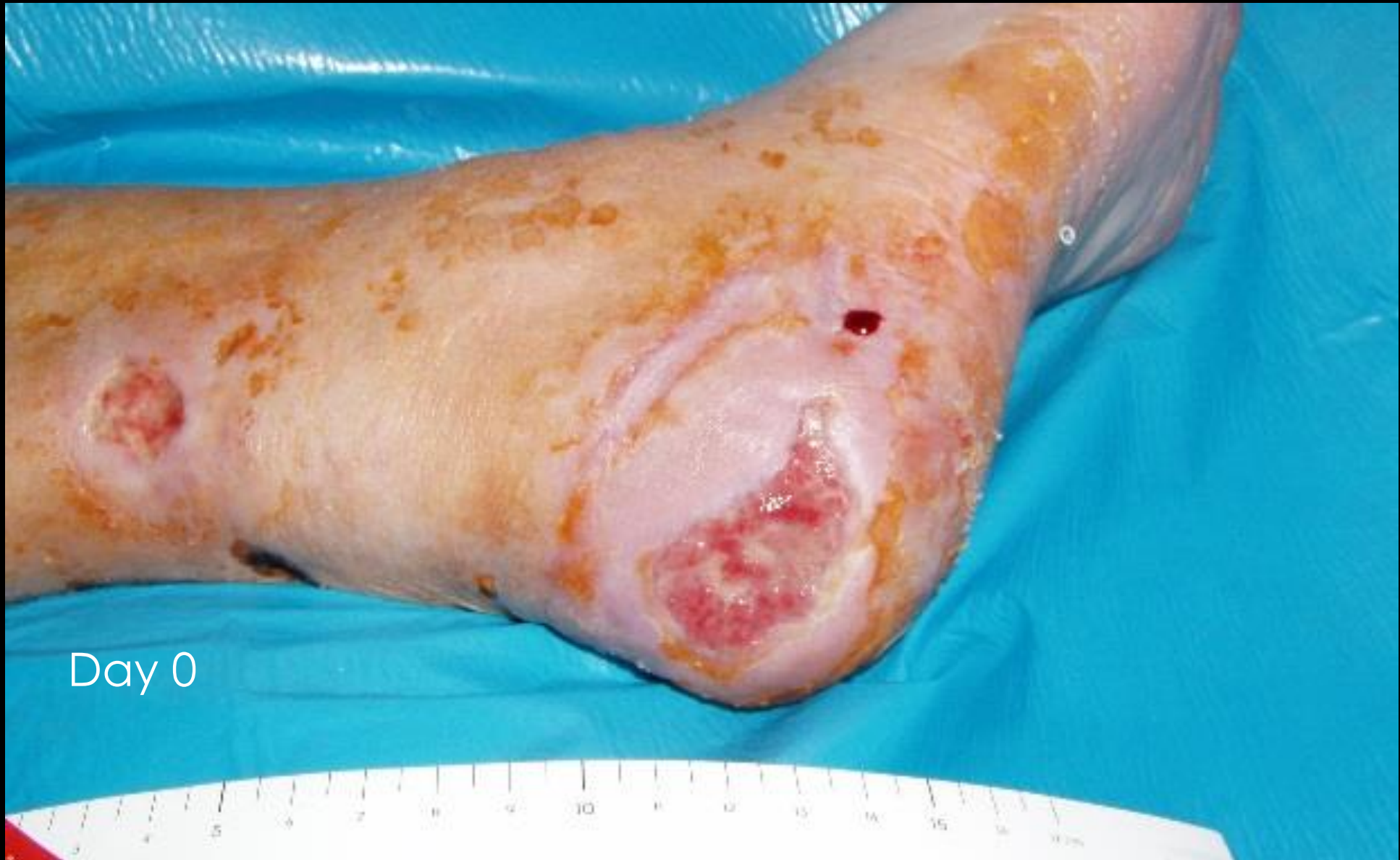


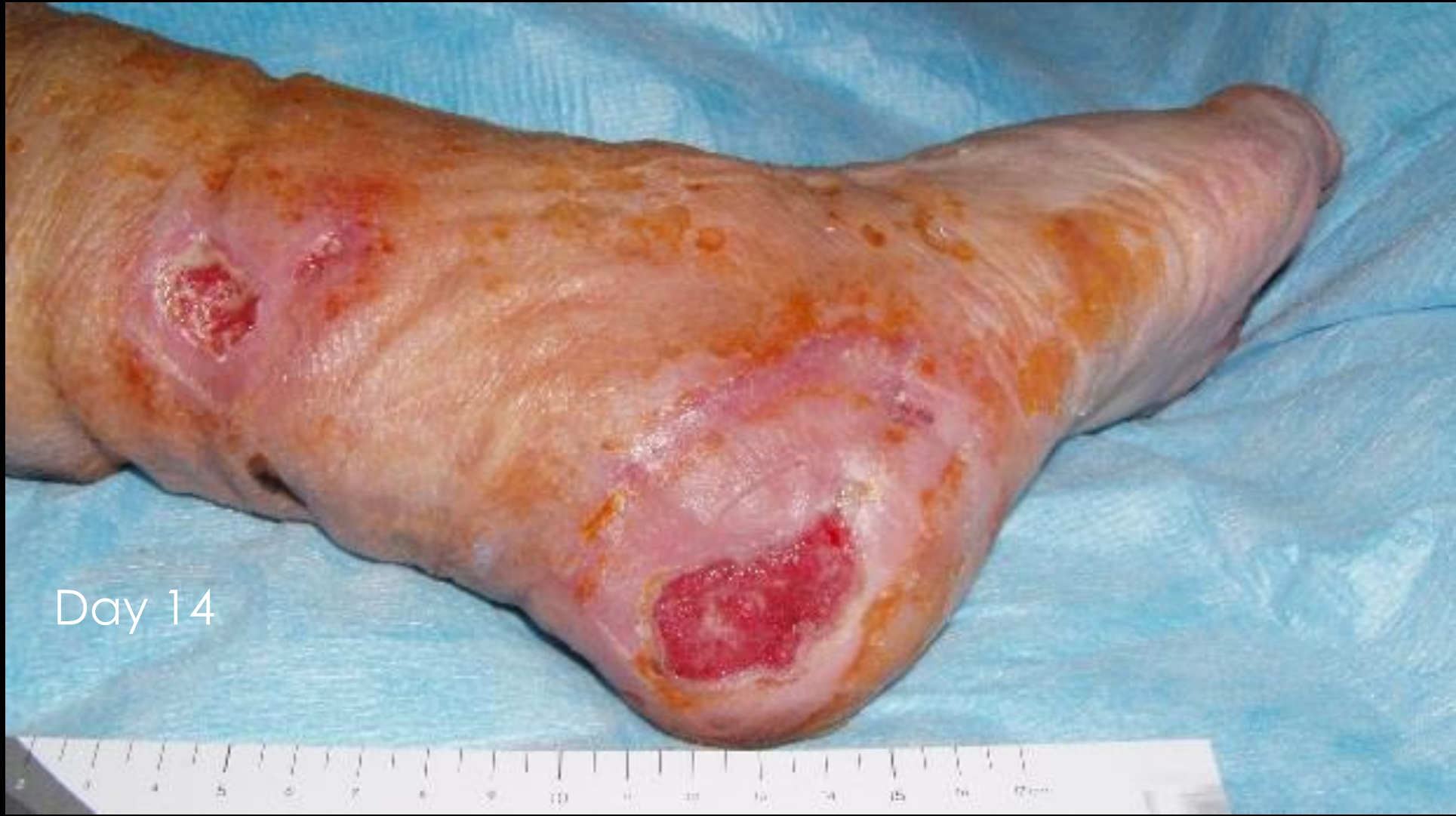
Case study I

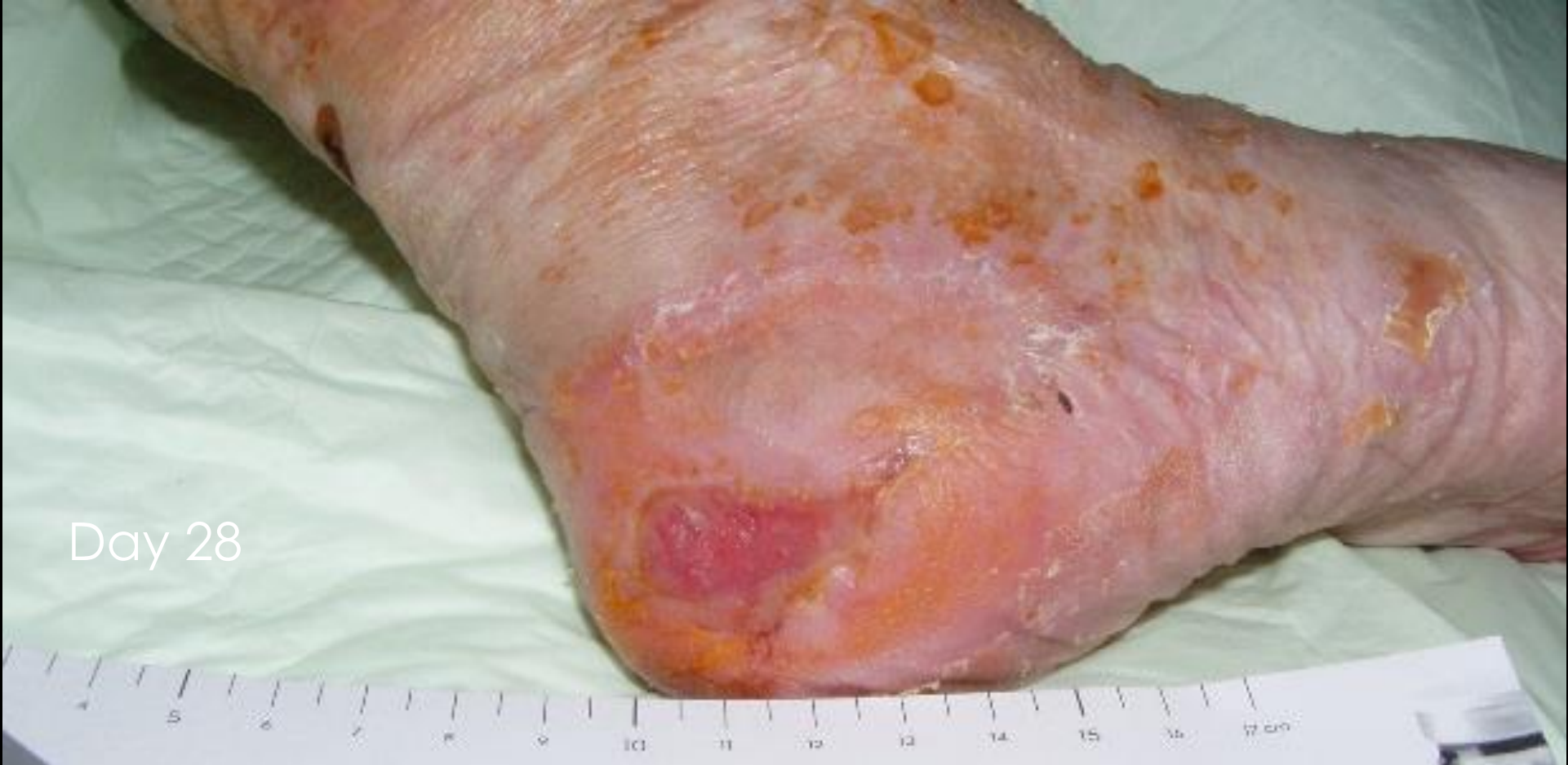Patient I: women, 78 years old, leg ulcer, cardiac ischemia, chronic obstructive pulmonary disease, lower limb ischemia



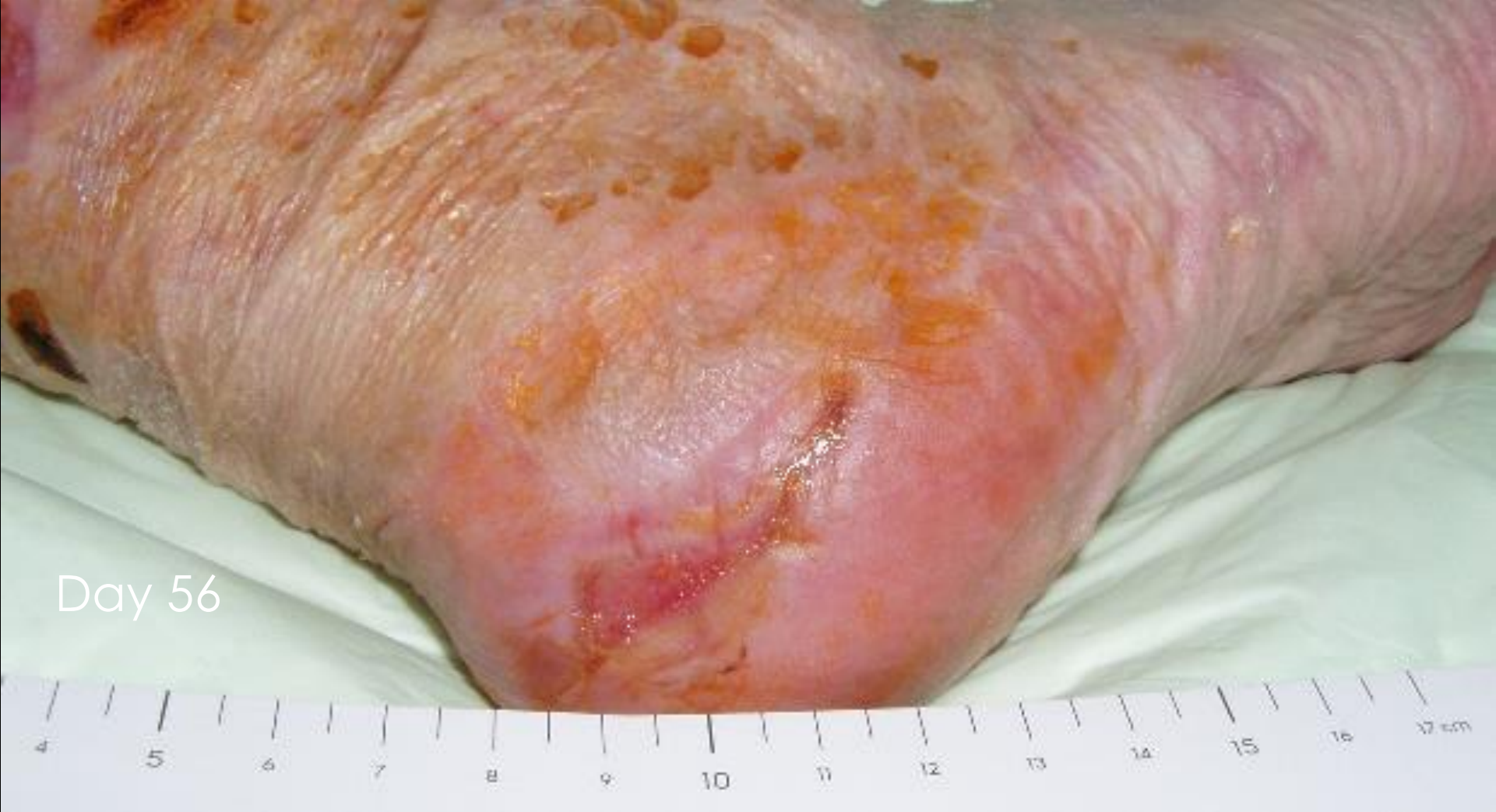Day 0



Day 14



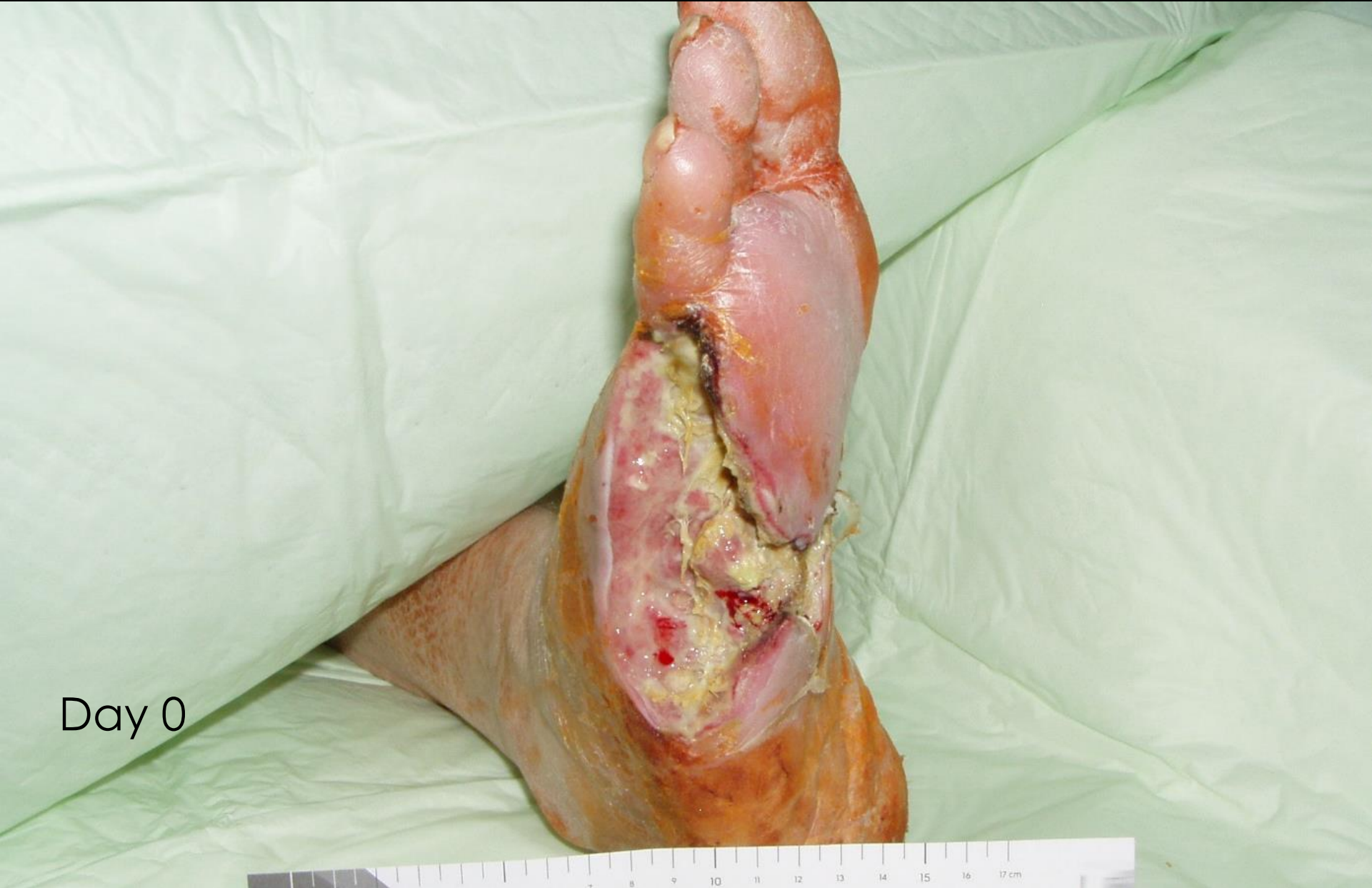Day 28



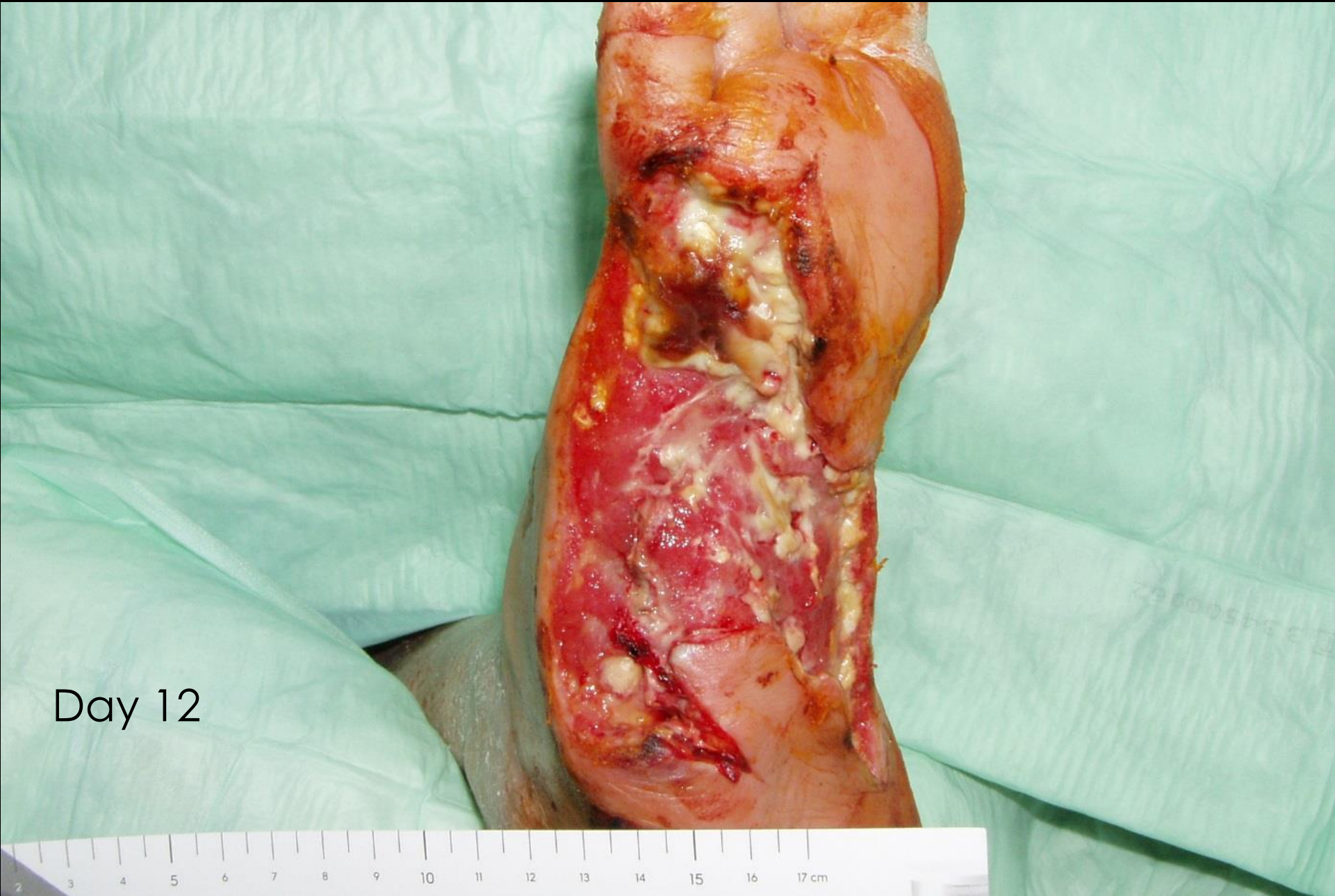Day 56

Case study II

Patient II: non-healing diabetic ulcer after amputation of the 4th and 5th toes, later the necessity of amputation of the 3rd and 2nd toes as well

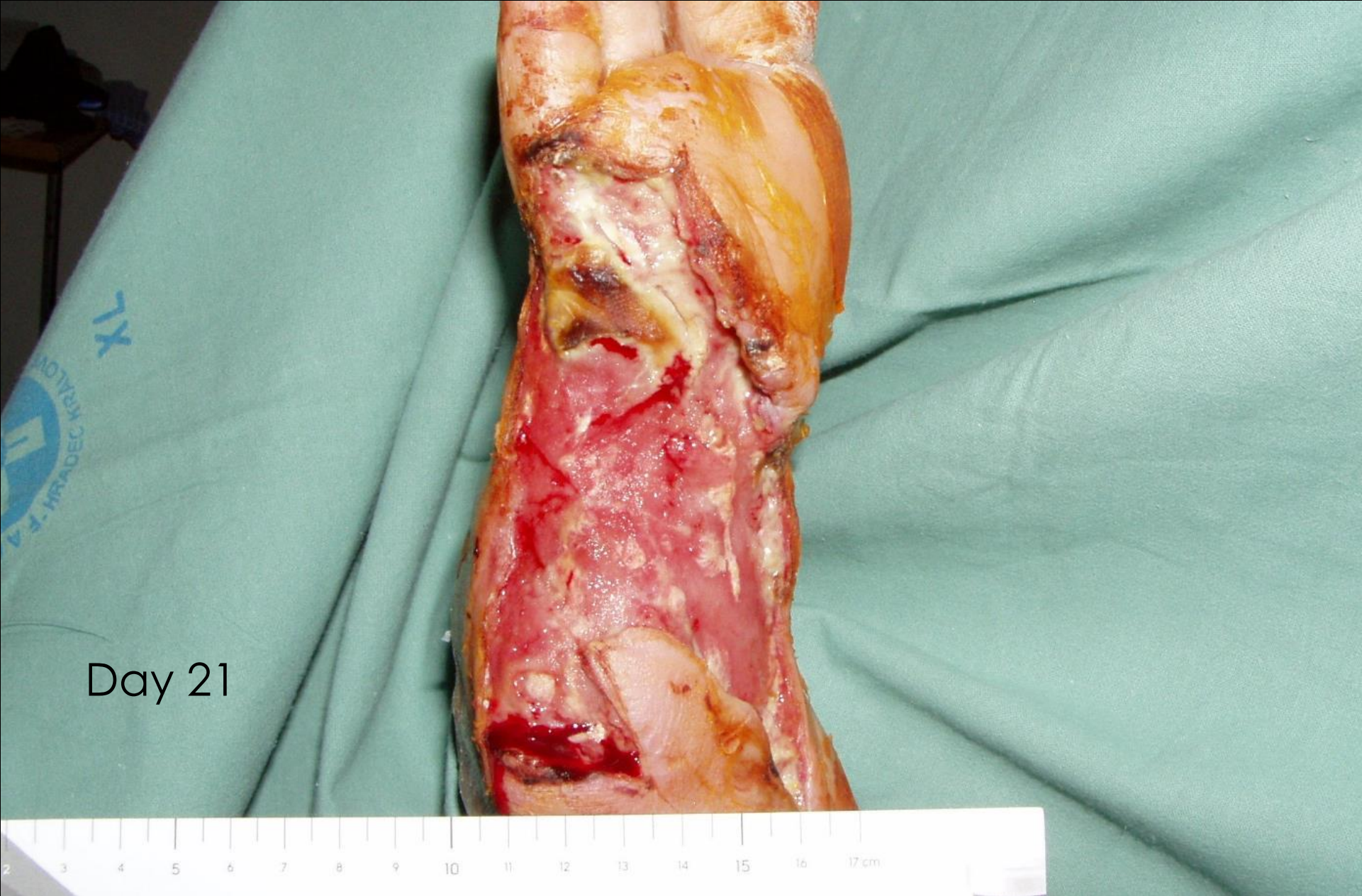


Day 0

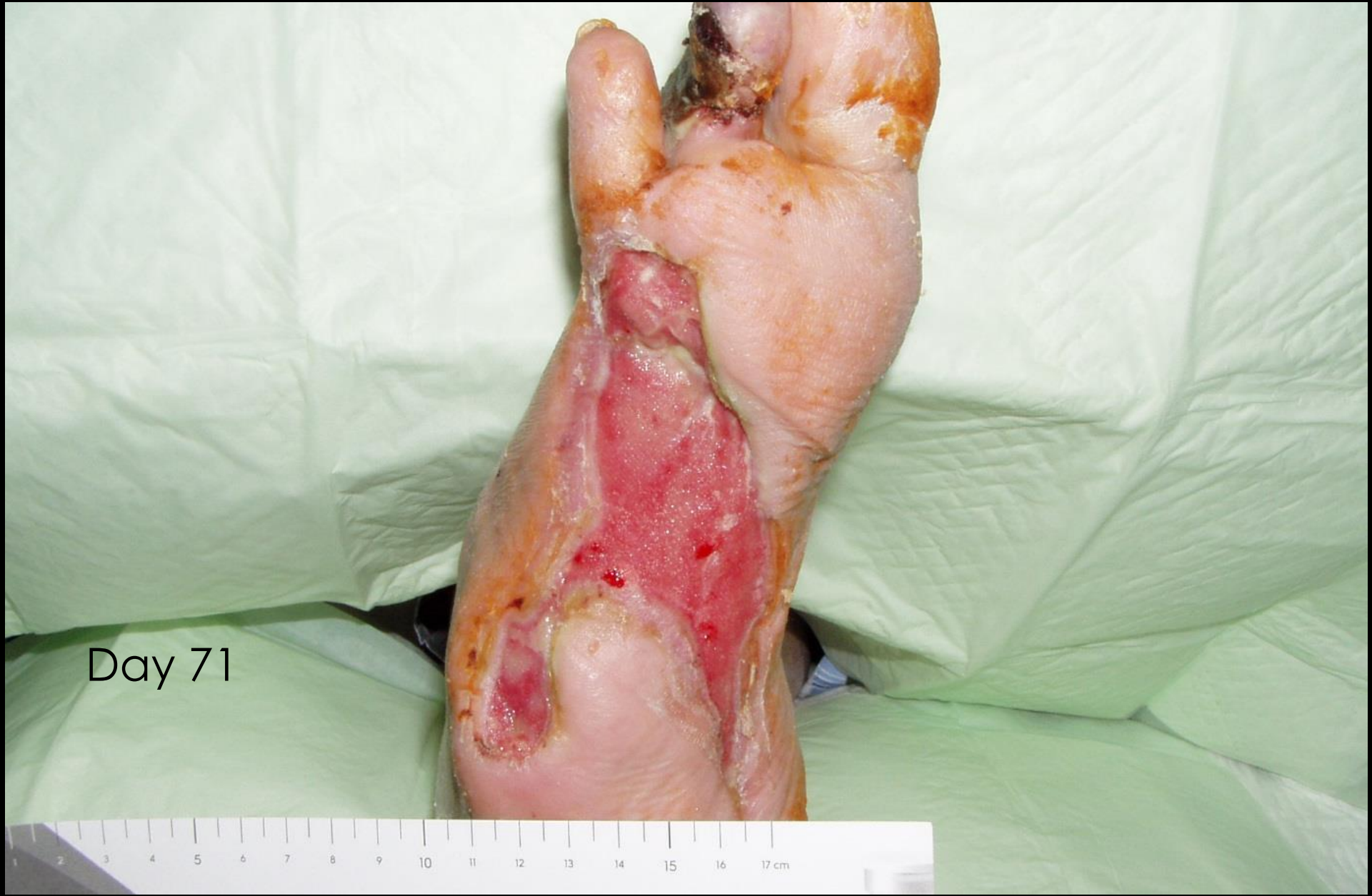

Day 12

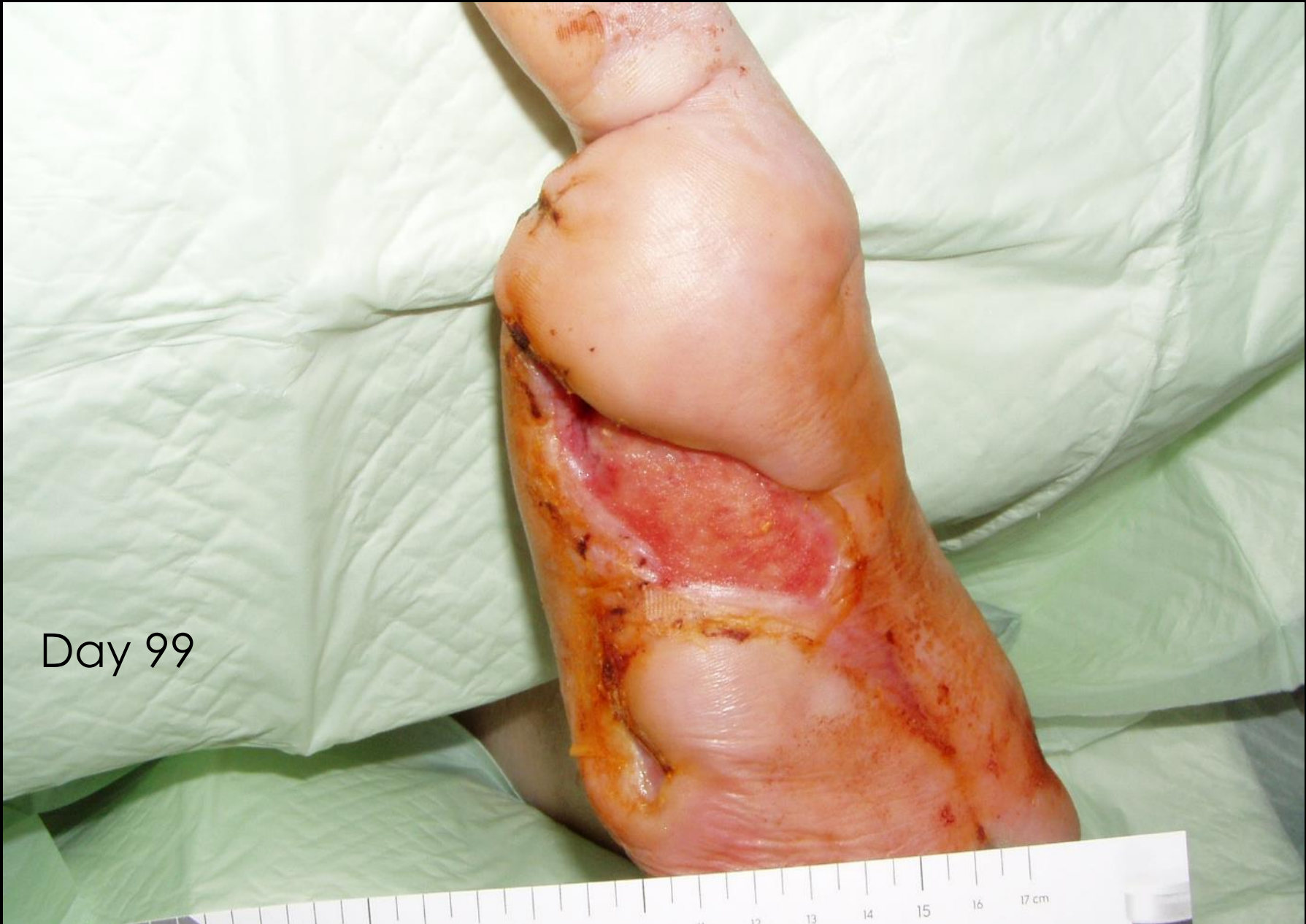



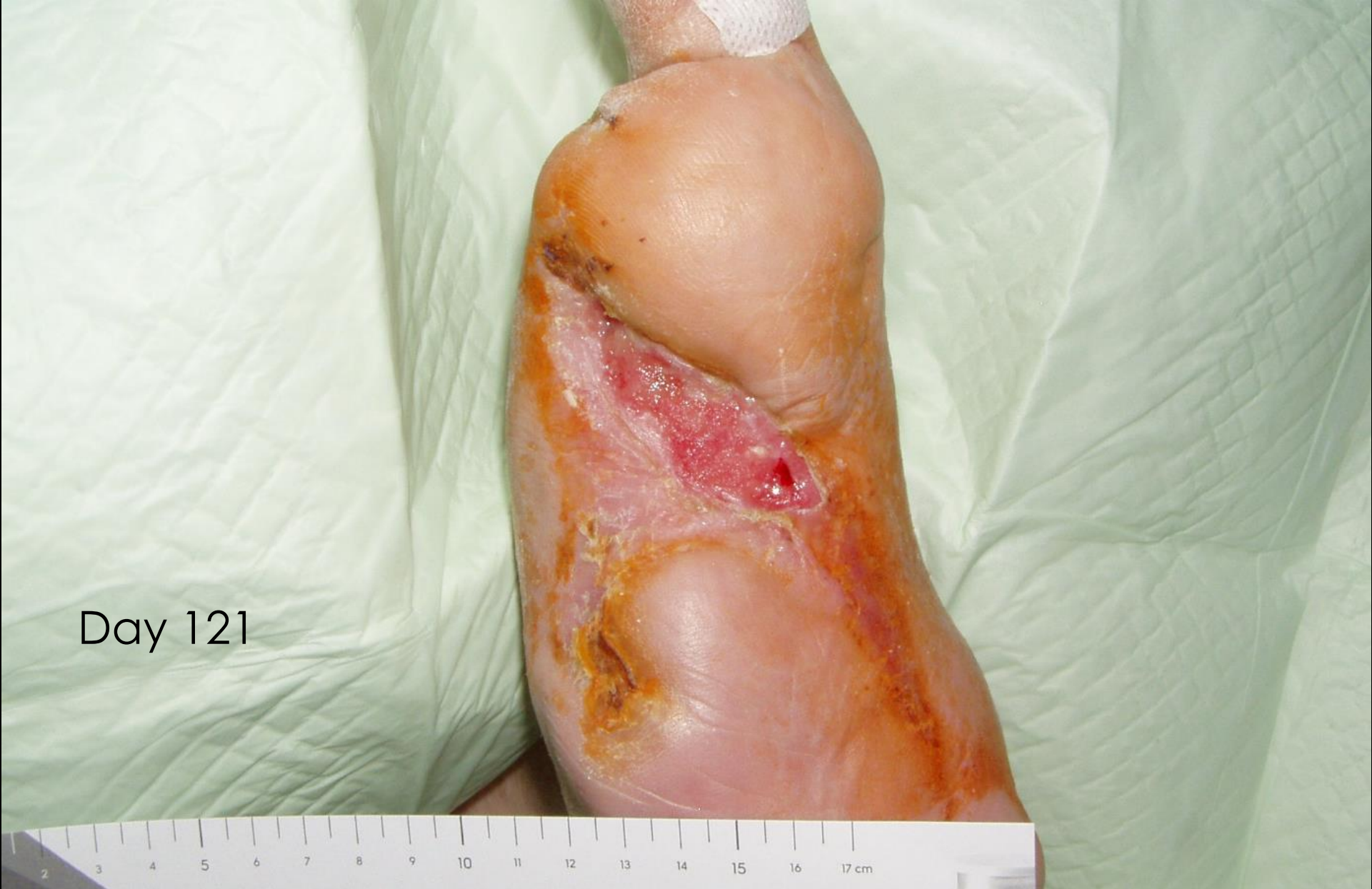Day 21



Day 71



Day 99

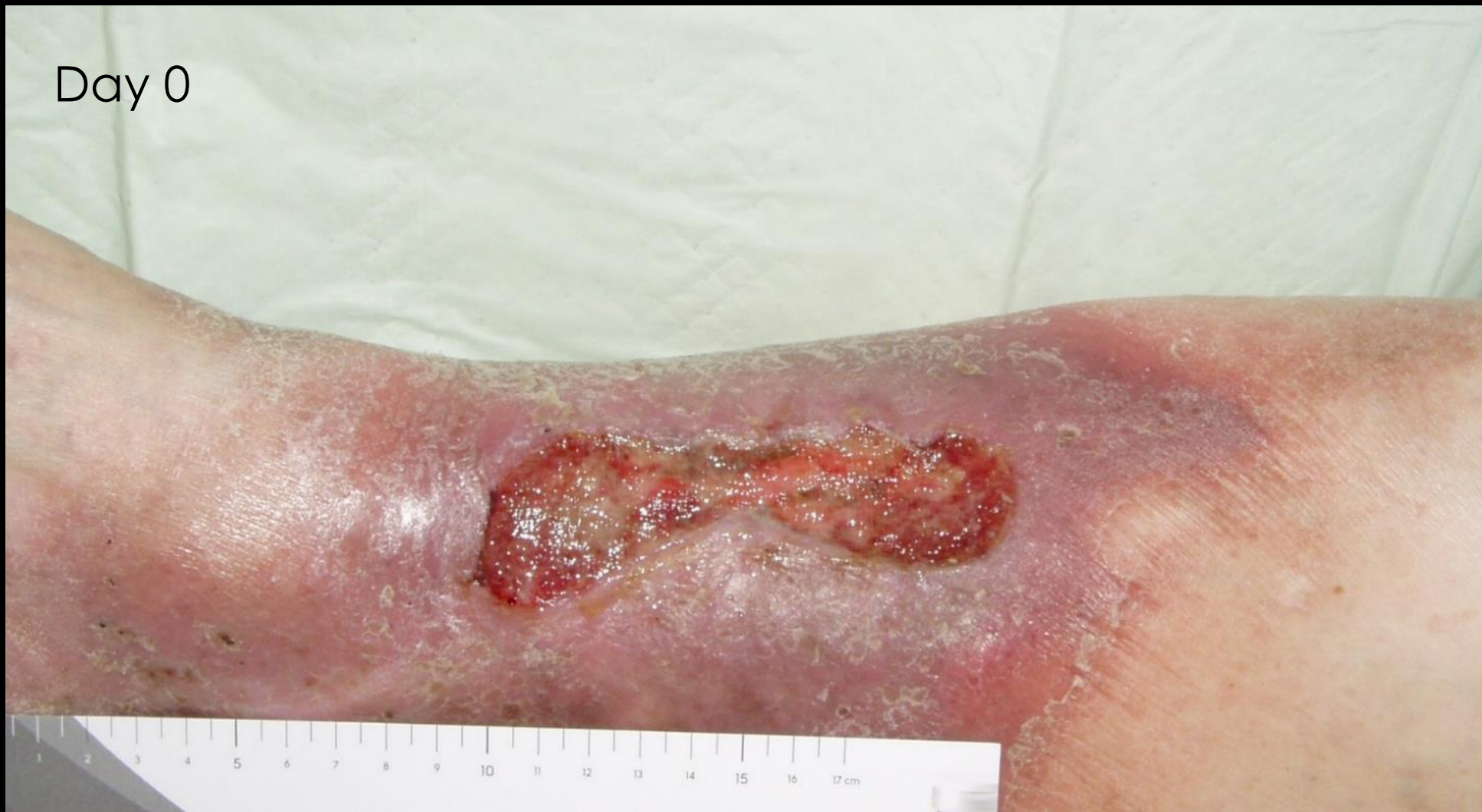

Day 121

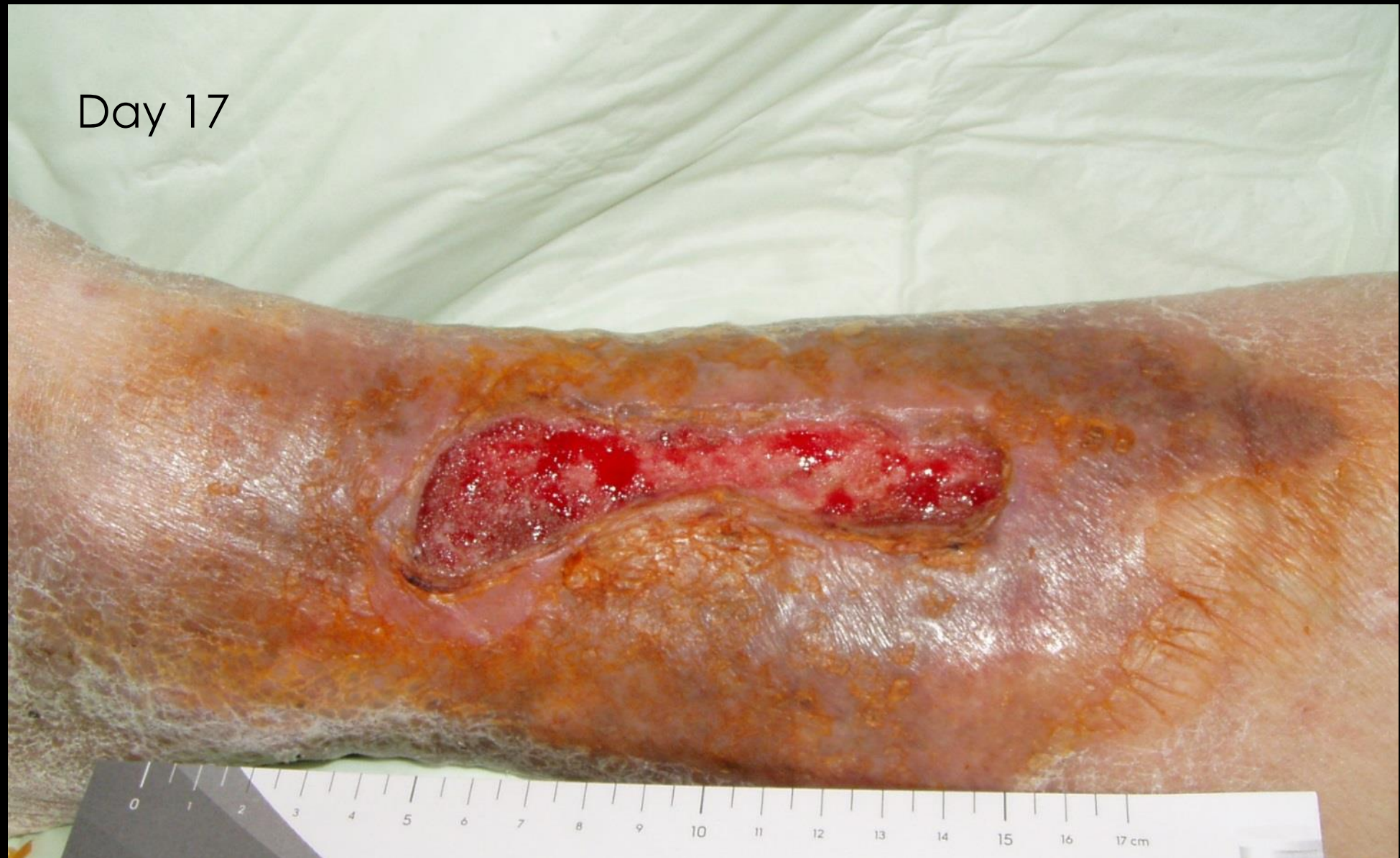Case study III

Patient III: women, patient suffering from chronic venous insufficiency, leg ulcer treated for 3 years, without result

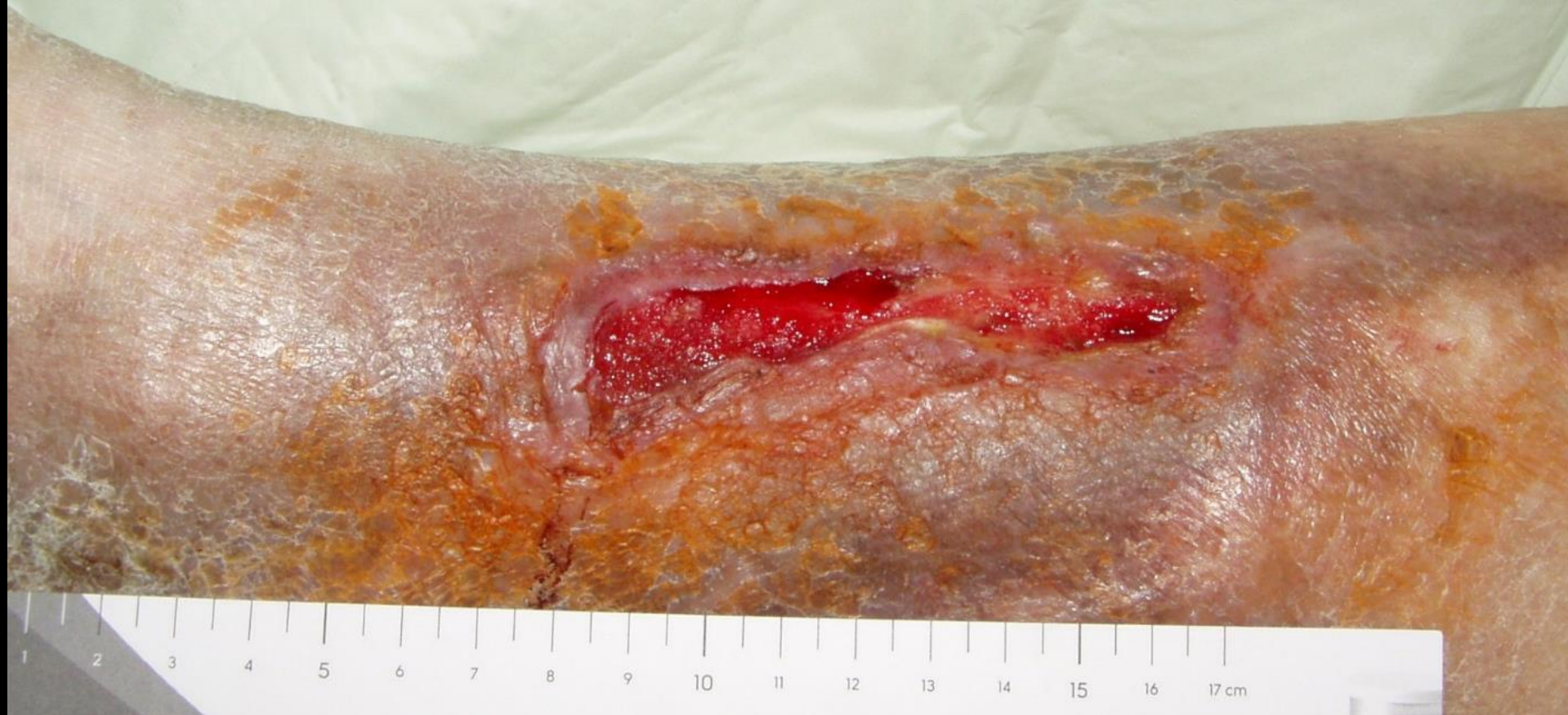Day 0



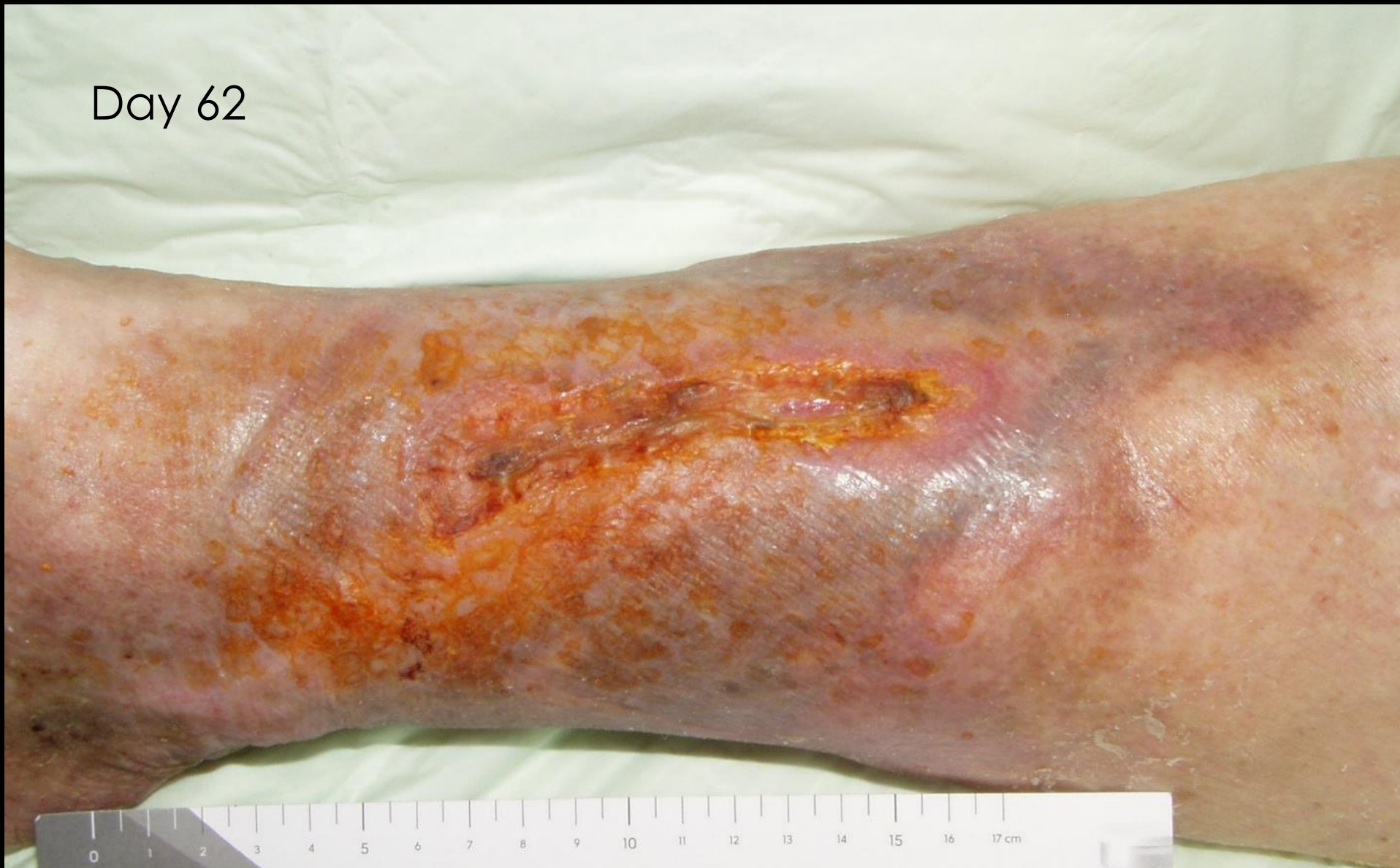Day 17



Day 42

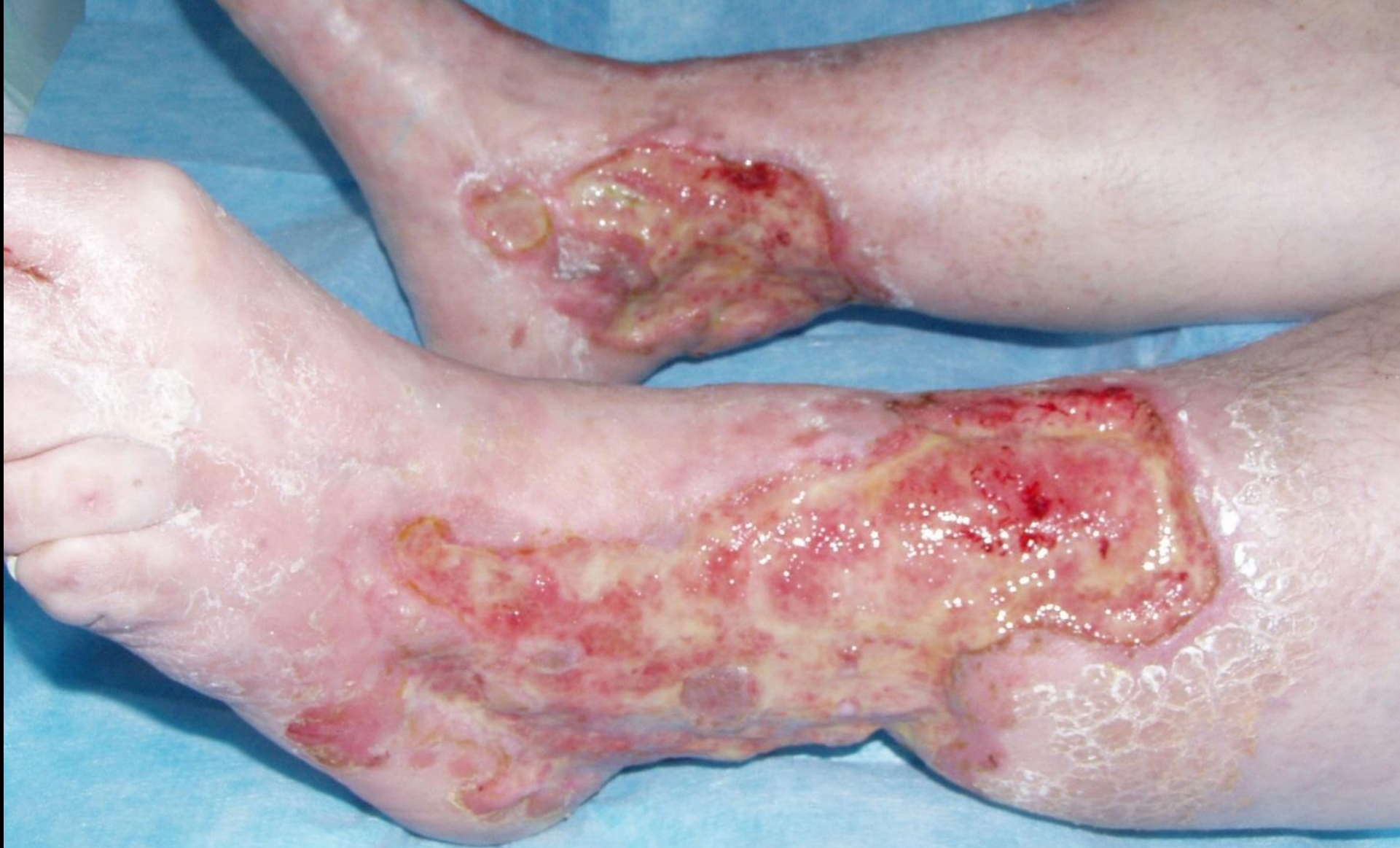

Day 62



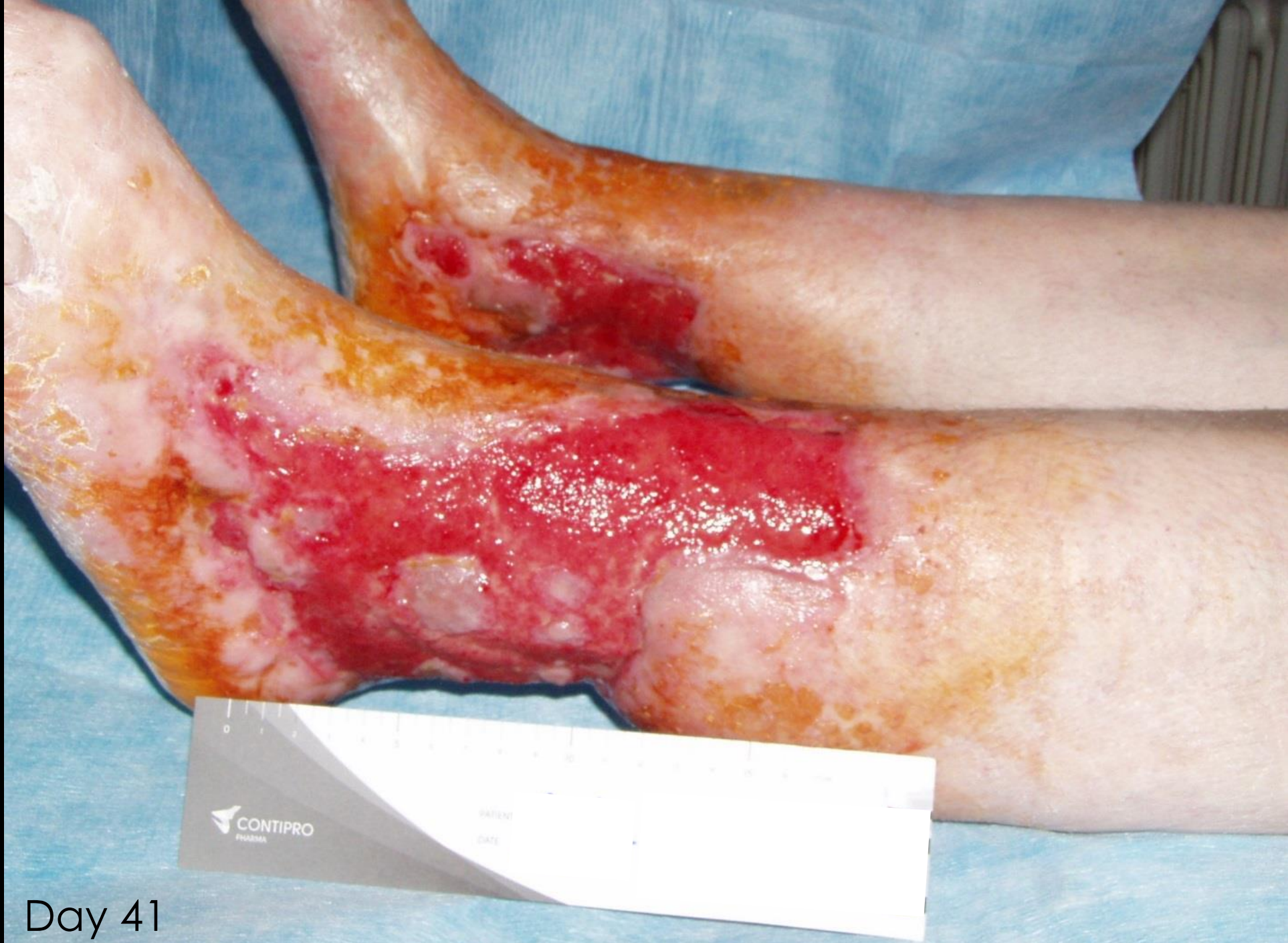
Case study IV

Patient IV: male, chronic leg ulcers for 20 years, available treatment methods failed, recommended amputation of left leg above the knee and right leg in the lower leg

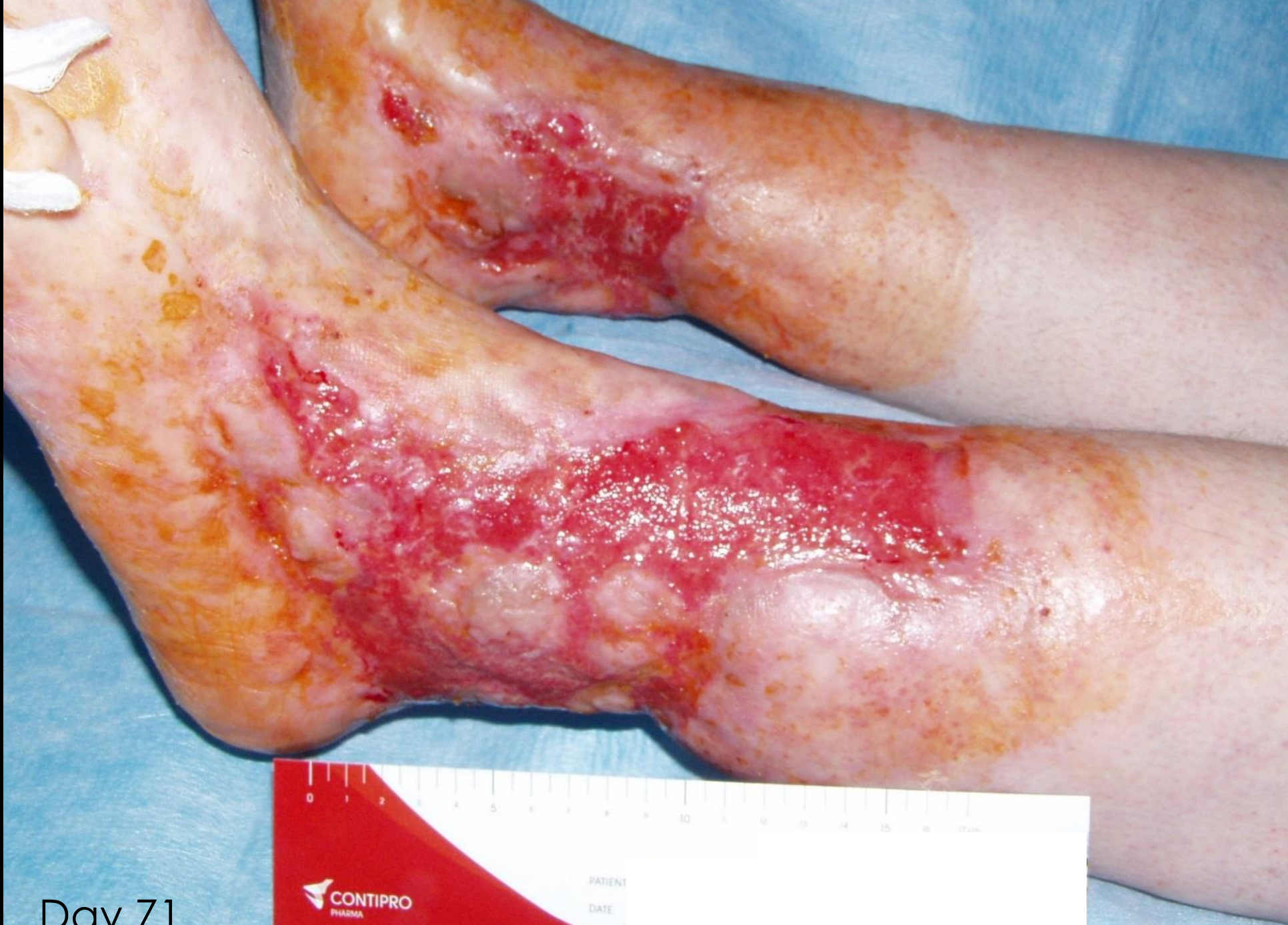

Day 0

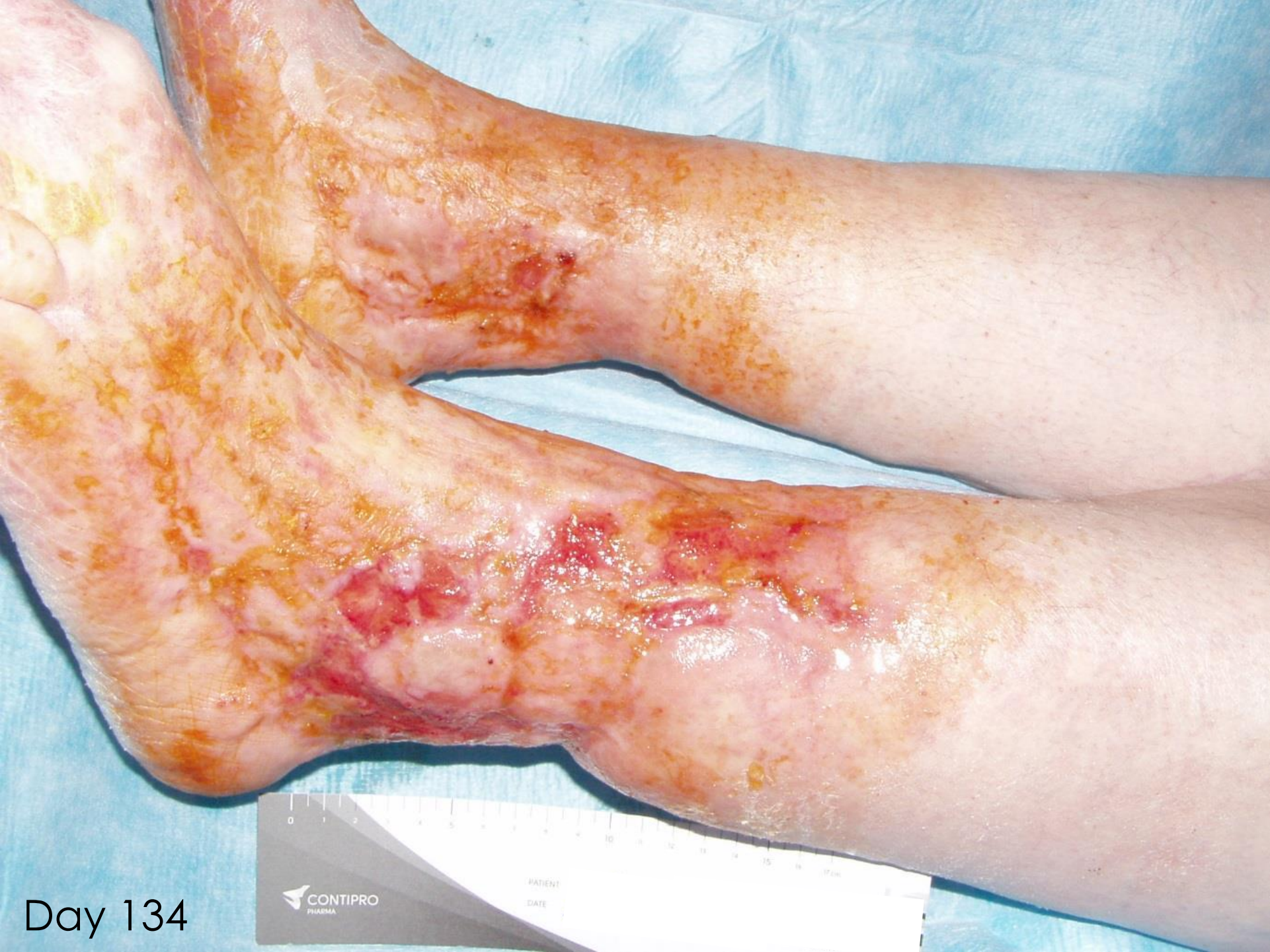



Day 41



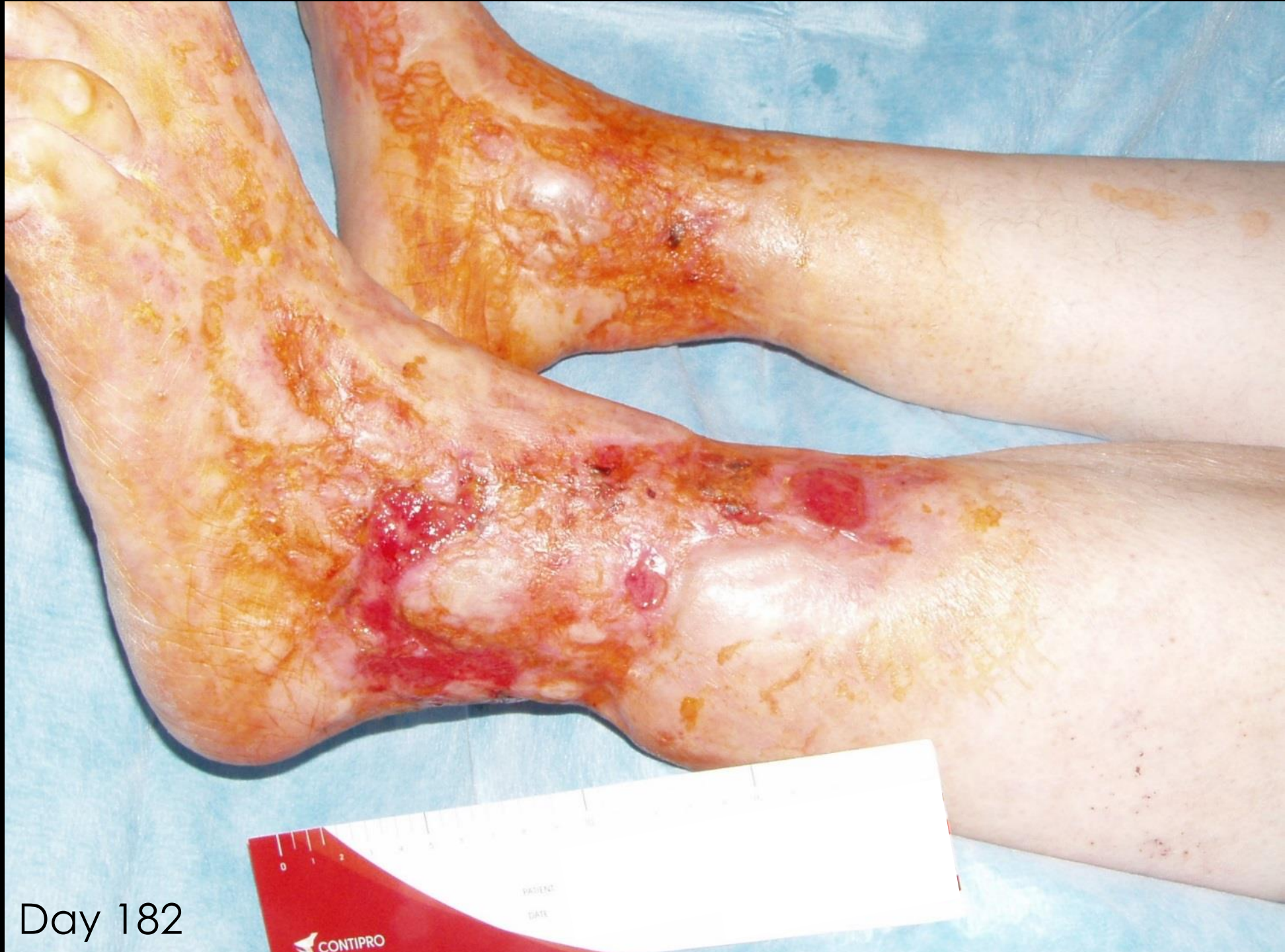Day 71



Day 134

CONTIPRO
PHARMA

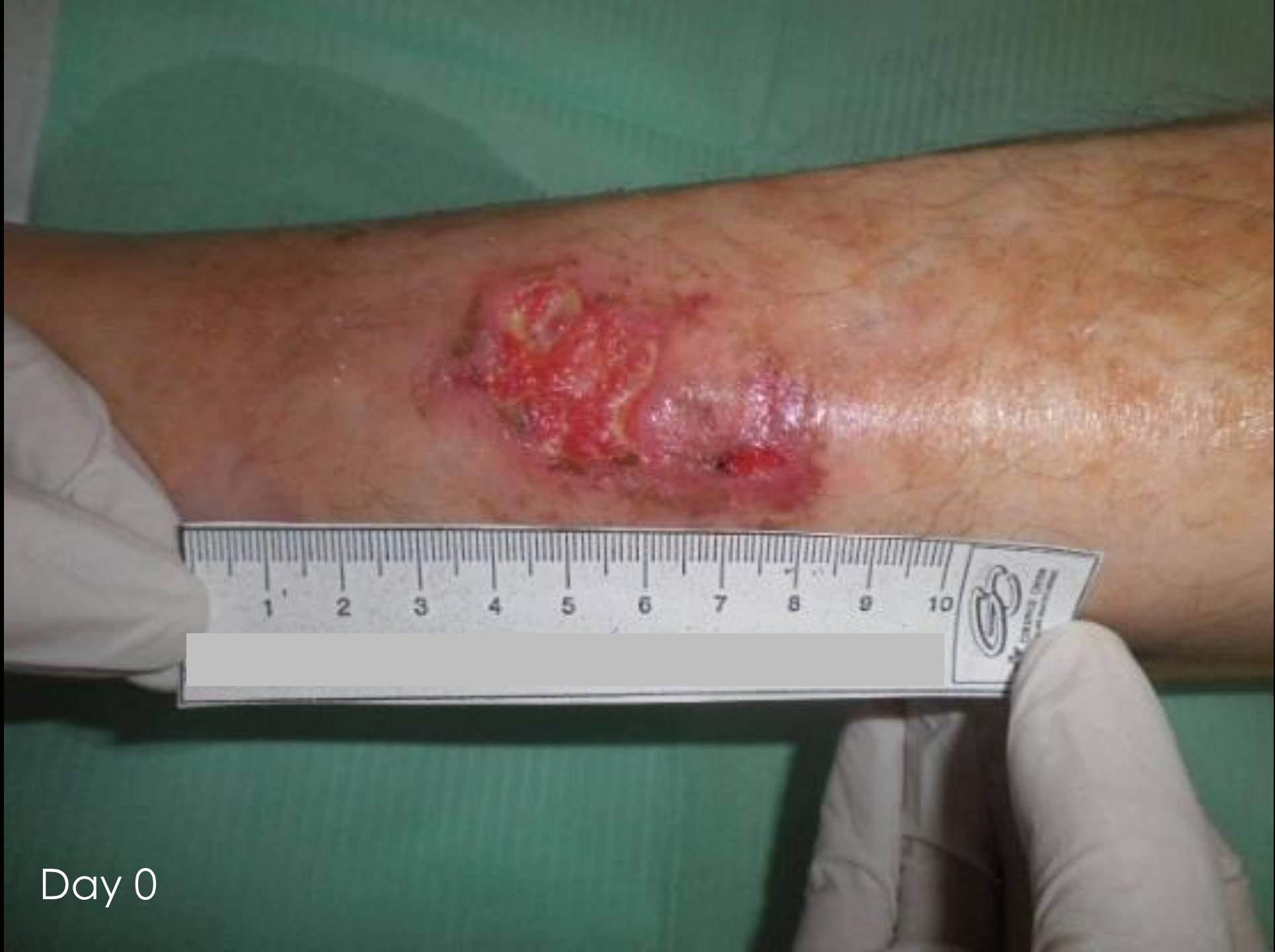PATIENT
DATE



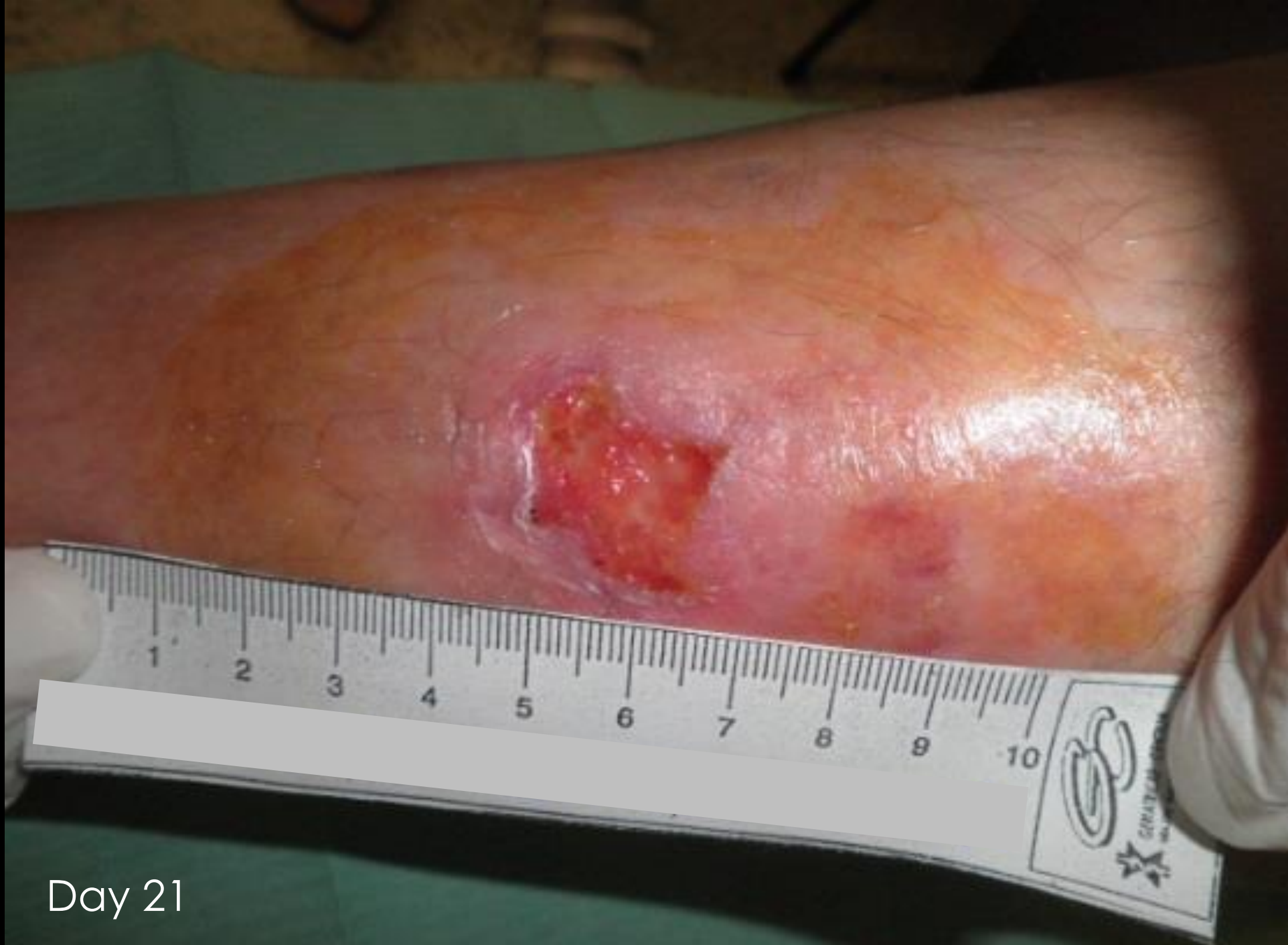Day 182

Case study V

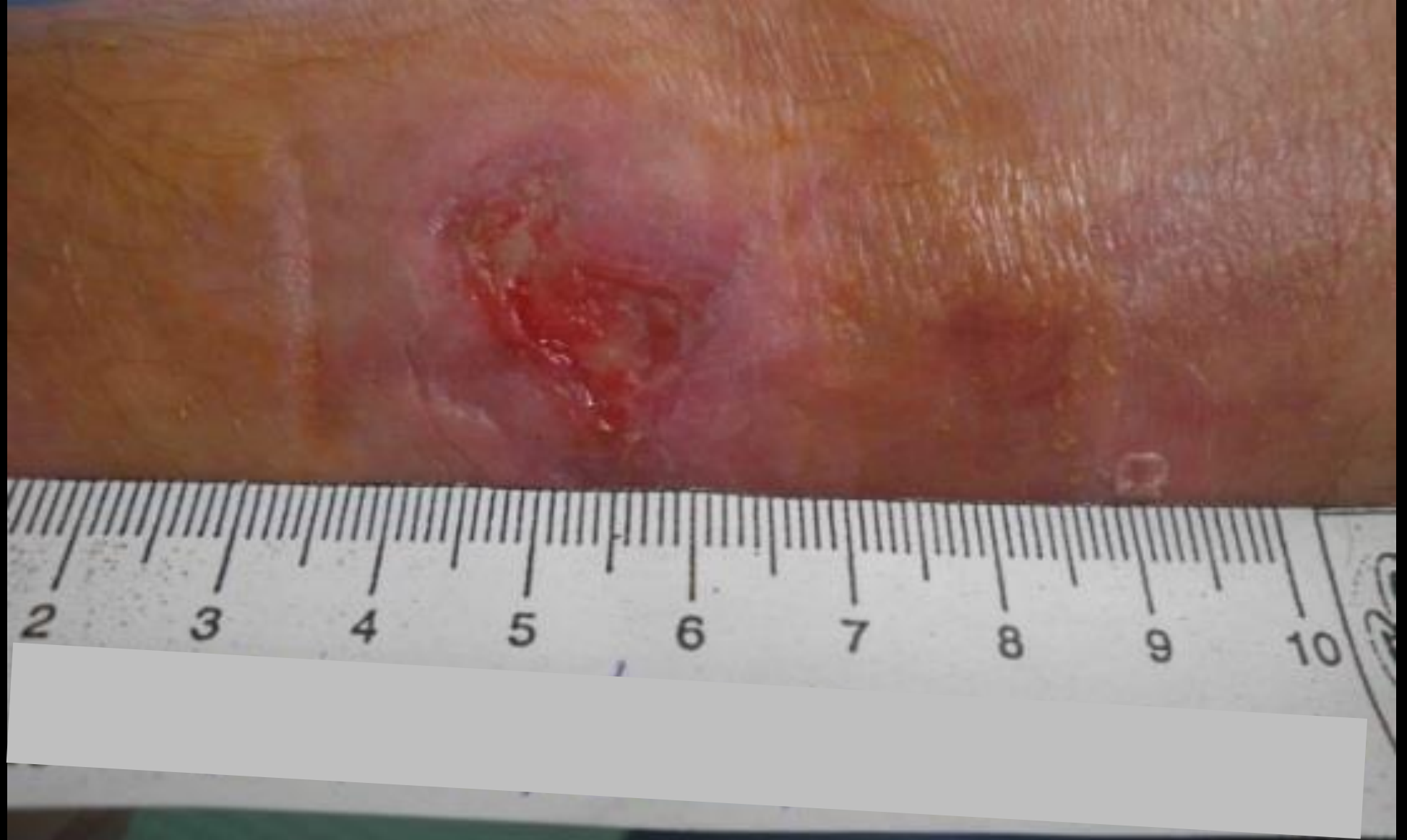Patient V: male, 54 years old, smoker, venous leg ulcer, spinal stenosis, arterial hypertension, asthma, hypothyroidism, hypercholesterolemia



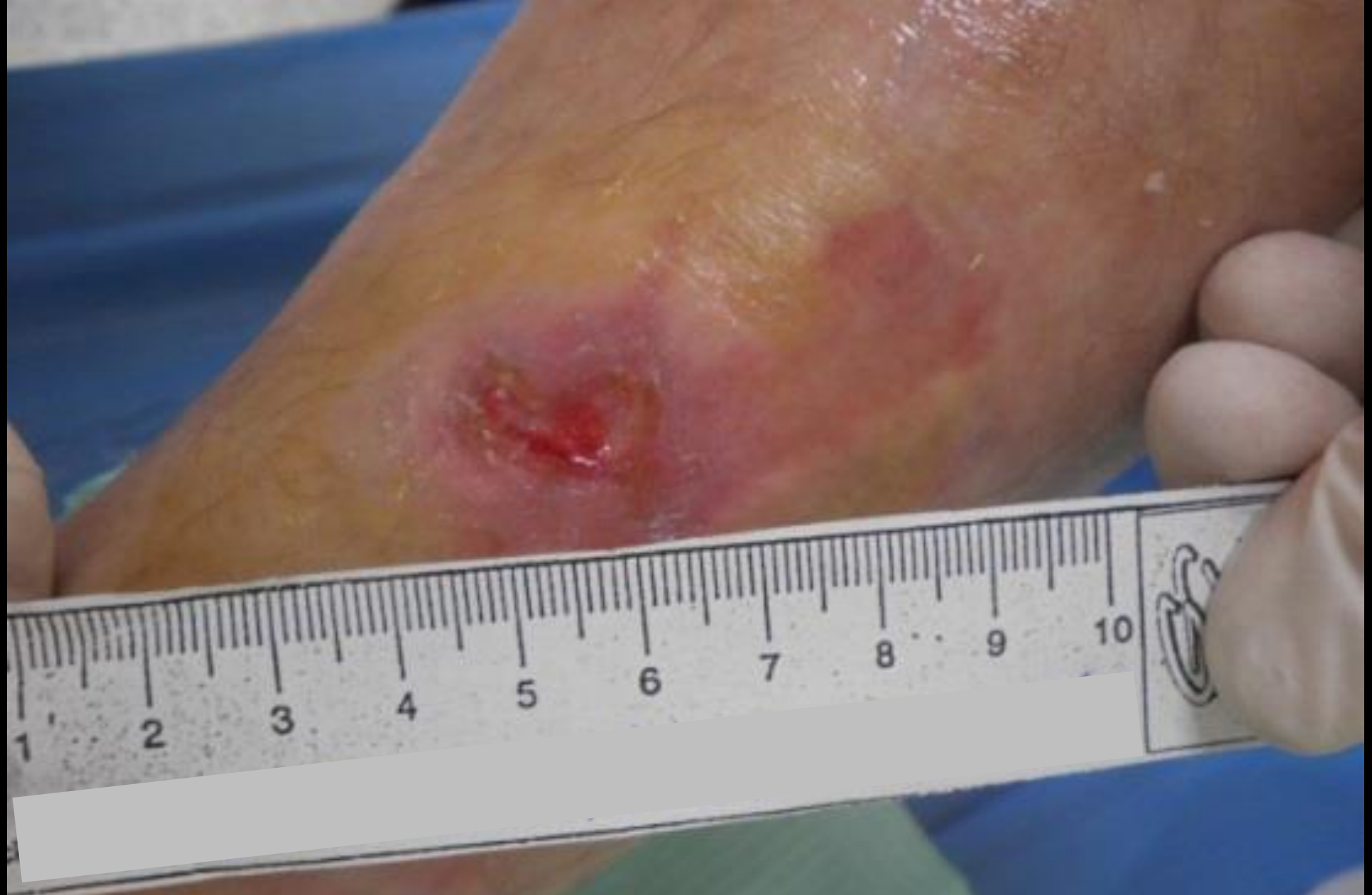Day 0



Day 21



Day 28

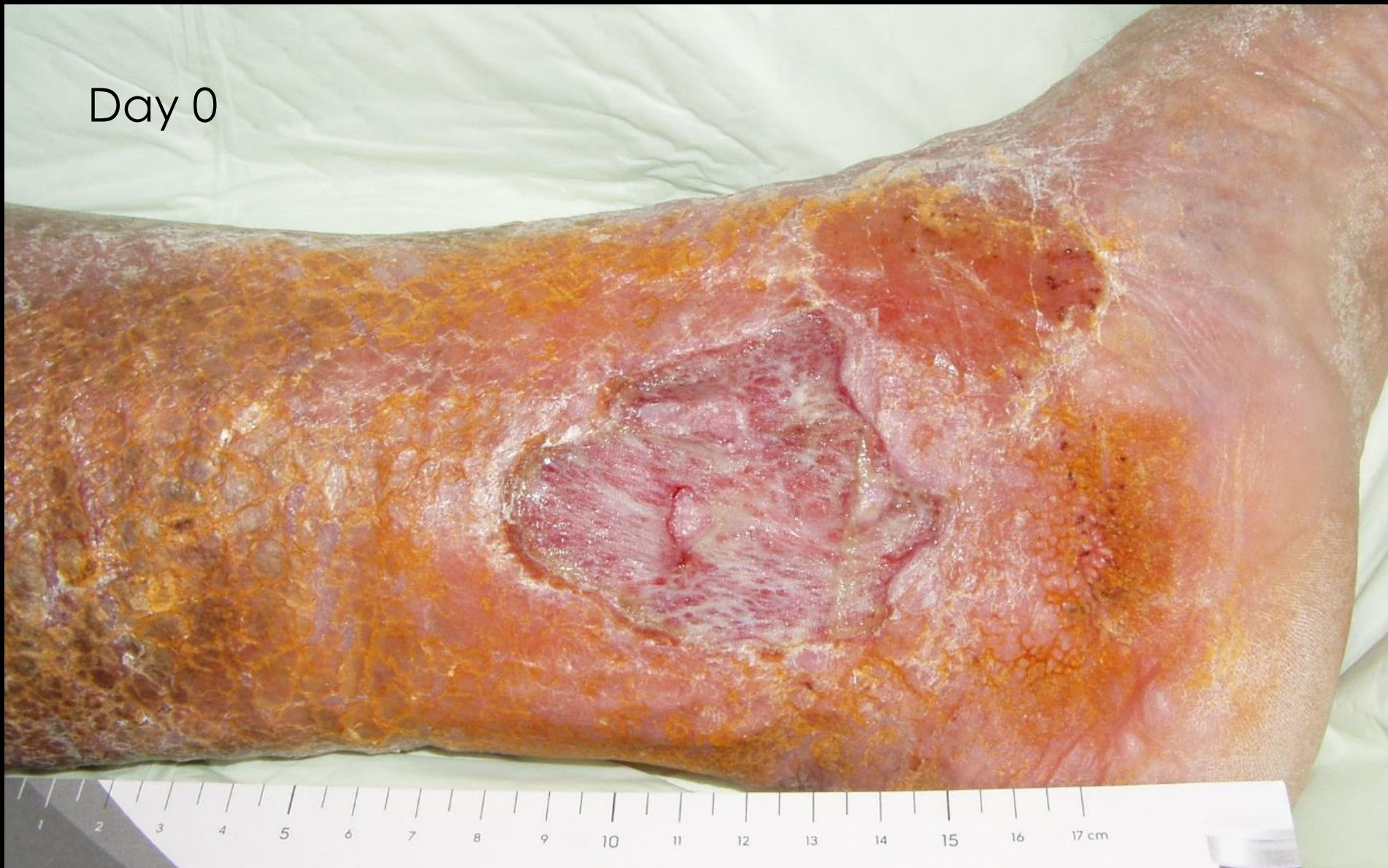

Day 35

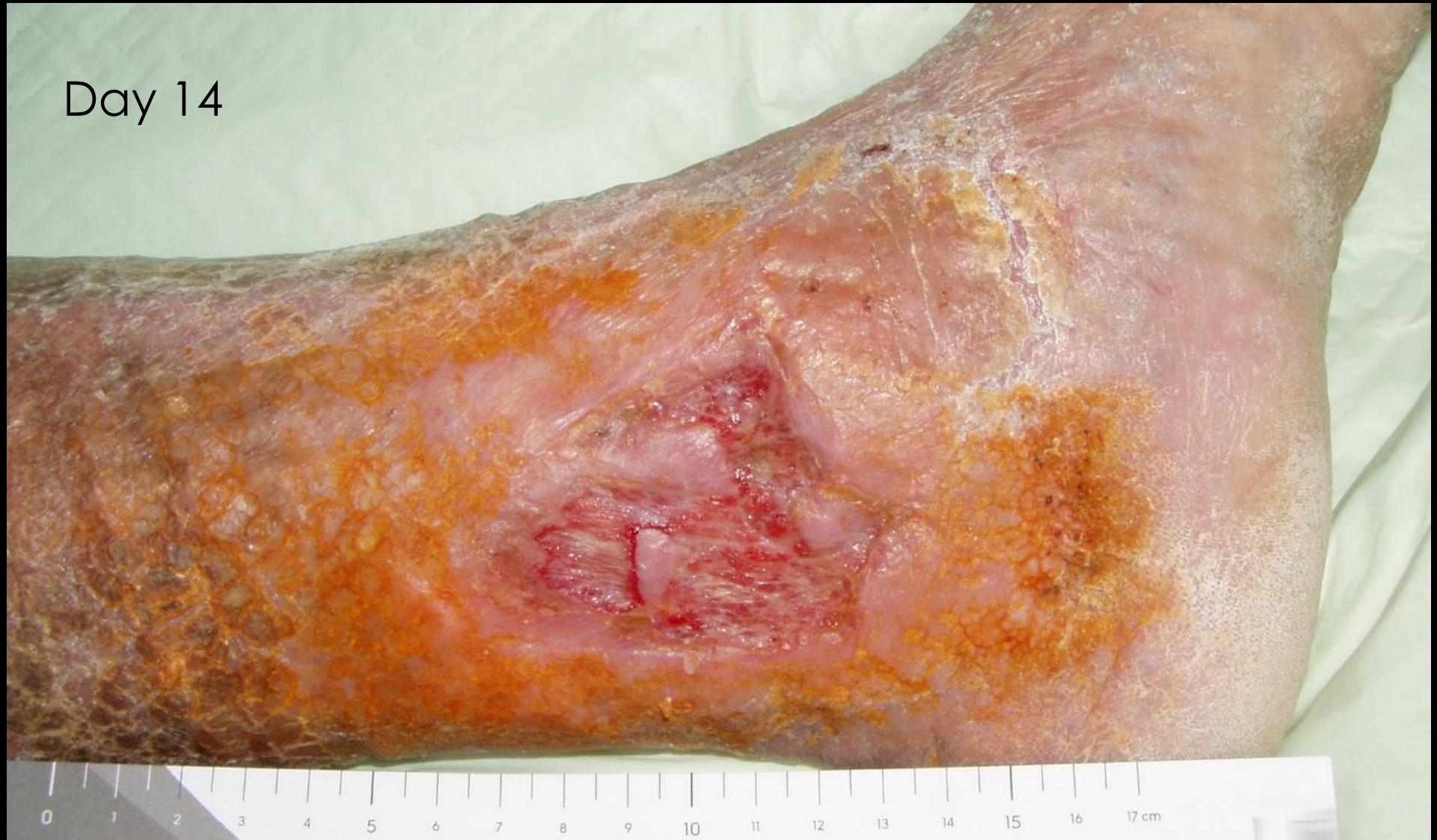Case study VI

Patient VII: chronic non-healing ulcer

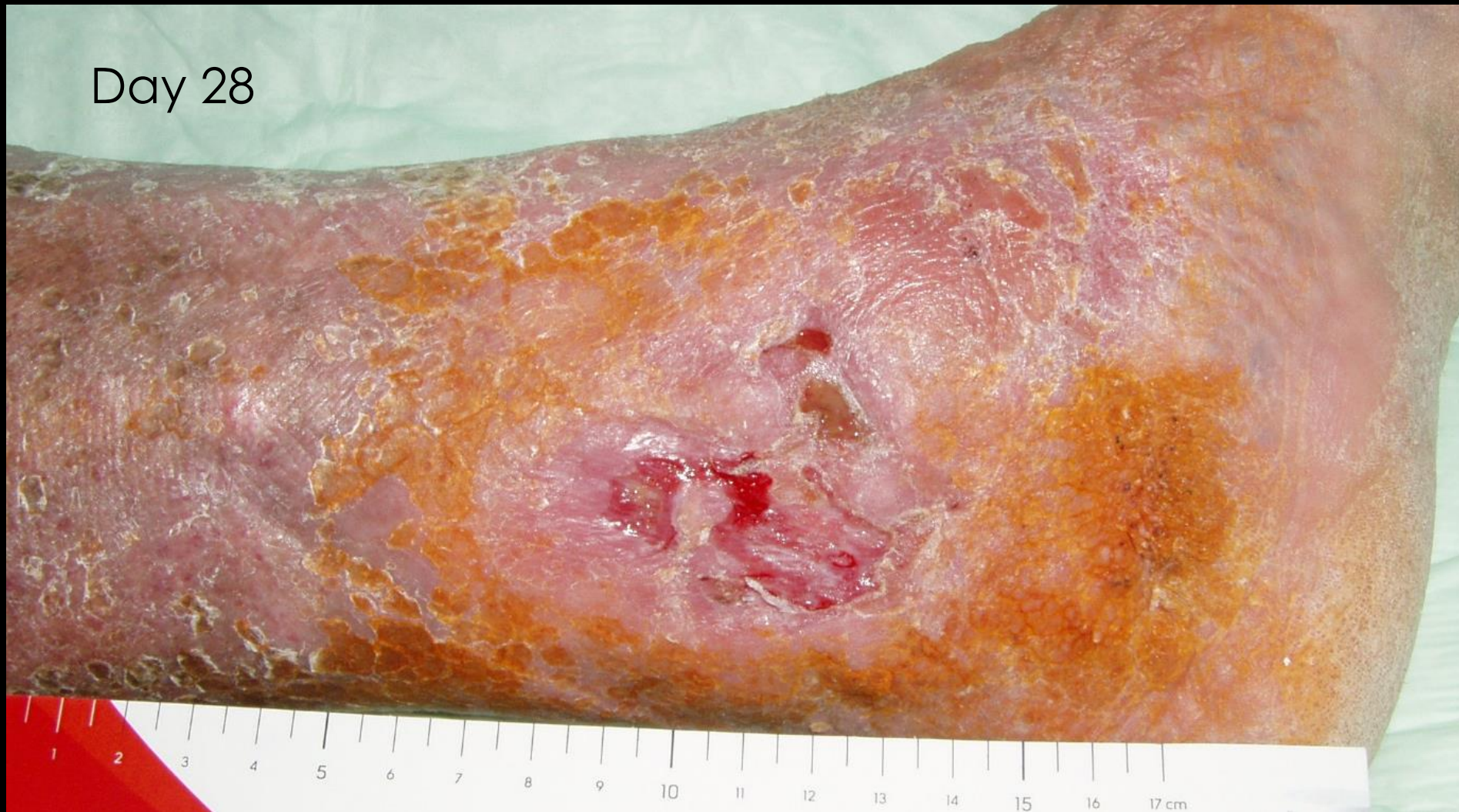Day 0



Day 14



Day 28



Day 35

